Demodikose beim Igel

Wieland Beck



Adspektion:

Signalement: Igel 1

Signalement: Igel 2

Signalement: Igel 3

Signalement: Igel 4

Signalement: Igel 5

Igel 1: Demodex erinacei
Igel 2: Trichophyton mentagrophytes var. erinacei
Igel 3: Zeckenbefall
Igel 4: Sarcoptes scabiei
Igel 5: Flohbefall

Anamnese: Wildlebender Igel wurde aufgefunden mit kranialem Stachel-ausfall & borkigen Hautveränderungen im Kopf- & Nackenbereich

Igel 1

Alopezie, blätterteigähnl. Schuppenbildg. infolge massiver Demodikose

D. erinacei parasitiert in Talgdrüsen d. Haarbälge u. verursacht krustige Verdickungen u.borkige Auflagerungen.

Differenzialdiagnosen:

Ektoparasitosen:

- Zecken (Ixodes hexagonus, Ixodes ricinus)
- Milben (Demodex erinacei, Notoedres oudemansi, N. cati, N. muris, Caparinia tripilis, Sarcoptes scabiei)
- Flöhe (Archaeopsylla erinacei)
- Fliegen (Lucilia sericata)

Dermatophytosen:

- Trichophyton mentagrophytes var. erinacei, u.a.

Dermatose anderer Genese:

- Vitamin-, Mineralstoffmangel
- Hormonstörungen
- Haltungsfehler (UV-Licht)

Diagnostik:

- Klinik
- Hautgeschabsel bis Blutpunkte erscheinen, Aufhellung mit KOH, Mikroskopie

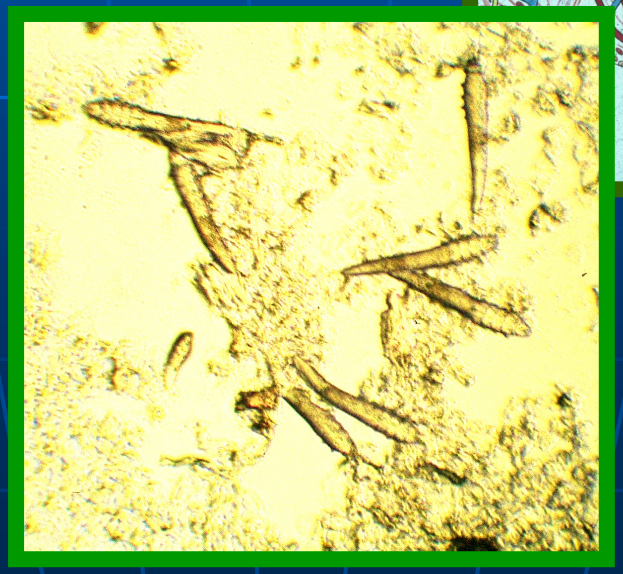

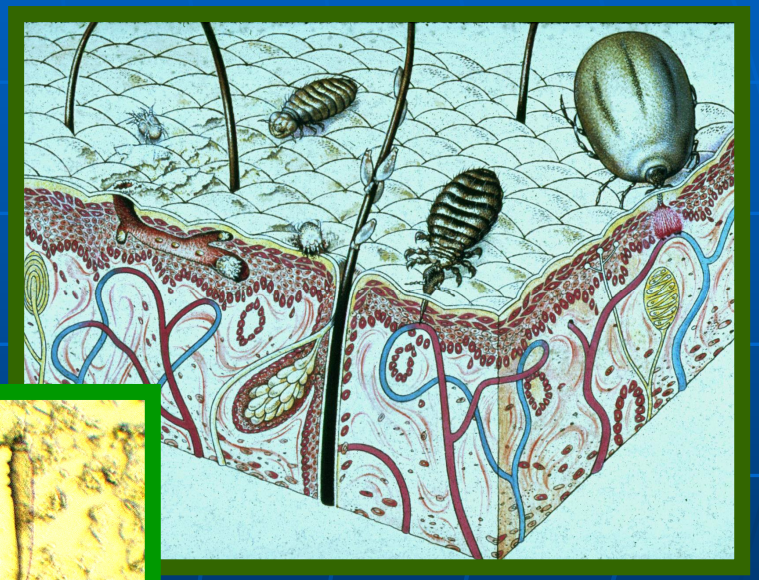

- ***Pilzkultur (Dermasel-Selektivagar), Mikroskopie: Laktophenolblaufärbung der Mikrokonidien***

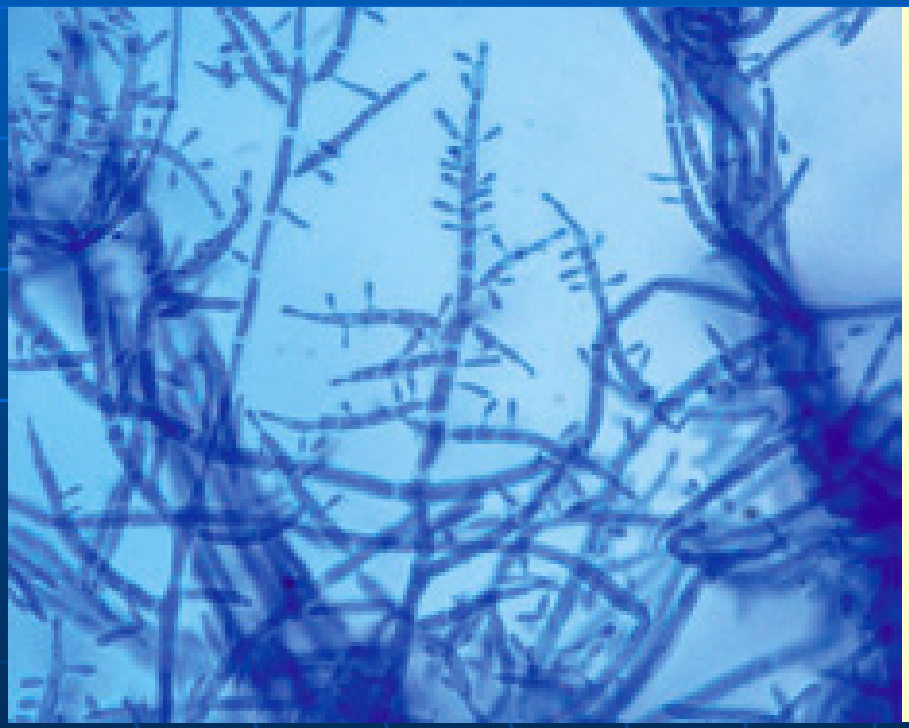

Therapie:

a) Spot-on-Behandlung mit Stronghold® 45 mg für Katzen von 2,6-7,5 kg KM im Nacken

b) 4x alle 3 Tage Imaverol®-Waschungen in einer 1:50 mit Wasser verdünnten Lösung (100 mg Enilconazol/ml)

c) 4 Wochen lang ¼ Tabl. Griseofulvin (25-50 mg/kg KM) mit etwas Futterbrei

d) Begleitend 0,5 ml Vit. A s.c.

Fazit:

- Nach 7 Tagen kein auffälliges Verhalten mehr.
- Nach 7 Tagen keine Milben mehr im Hautgeschabsel.
- Nach 14 Tagen Hautveränderungen weitgehend abgeklungen.
- Nach 4 Wochen Stachelkleid weitgehend wiederhergestellt.

Injektionstechnik beim Igel

- *Laterodorsal Hautfalte mit Pinzette ergreifen*
- *In Längsrichtung der Falte flach einstechen*
- *Kanüle muß unter Haut frei beweglich sein*
- *Keinesfalls zu weit lateral o. ventral stechen, da beim Einrollen Gefahr der intrapulmonalen bzw. intraperitonealen Injektion*
- *Nicht im Schulterbereich stechen, weil dort im Fettgewebe schlechte Resorption o. Verletzung des Winterschlaforgans („braunes Fett“)*

Notoedric mange caused by *Notoedres cati* in a pet African pygmy hedgehog (*Atelerix albiventris*)

N. PANTCHEV, T. HOFMANN

THE African pygmy hedgehog (*Atelerix albiventris*) is a common pet in the USA (Rosen 2000) and is becoming more popular in Germany. In the wild, it lives in middle and western Africa, from Kenya to Senegal. Its body is 15 to 25 cm long and it weighs up to 650 g, slightly smaller than the European hedgehog (*Erinaceus europaeus*). The limbs are relatively long and the body is generally oval-shaped. It is characterised by its long, pointed nose.

Notoedric mange caused by *Notoedres cati* is an epizootic cutaneous disease of mammalian species in the Felidae (Bowman and others 2001), Procyonidae (Lavoipierre 1964, Valenzuela and others 2000, Ninomiya and Ogata 2002), Viverridae (Klompen 1992, Ninomiya and others 2003), Herpestidae and Leporidae (Klompen 1992) families. Notoedric mange caused by *Notoedres oudemansi* has been described in free-living African pygmy hedgehogs in the Nairobi area of Kenya (Gregory 1981): it affected nine (6·5 per cent) of 140 animals, with a high mortality rate. The affected animals were male only, and showed alopecia and encrustation on the hairy (not spiny) parts of the body and face, whereas the lower part of the legs was relatively unaffected. *Notoedres muris* mites have been observed in European hedgehogs from New Zealand (Heath and others 1971). This short communication describes the first case of notoedric mange caused by *N cati* in an African pygmy hedgehog.

A one-year-old, female African pygmy hedgehog was presented. It had been with the current owner for 10 months and had not been in veterinary care previously. It had been bred in Germany for the pet trade and had been purchased at a German trade show for exotic animals. According to the trader, the parents were wild hedgehogs that had been captured in Tanzania. When the owners returned home to their pet after a two-week holiday, the hedgehog had a large crust formation on its head, and a veterinary surgeon was consulted immediately.

Physical examination revealed that the animal was in a good condition, with a bodyweight of 342 g. Dermatological examination revealed massive crust formations on the head, ears, carpal and pad region (Fig 1). The crusts were white and yellow, and very thick and hard. No other animals were kept in the household, and none of the family members was suffering from dermatological lesions.

The hedgehog was anaesthetised for diagnostic tests, using isoflurane/oxygen inhalation. Samples of crust material from the affected skin were taken and submitted to the diagnostic laboratory for examination for ectoparasites and dermatophytes. The suspicion of mite infestation led to initial treatment with 0·3 mg/kg moxidectin (Cydectin 1 per cent injectable; Fort Dodge), administered subcutaneously, which was repeated after 10 days, in combination with daily topical administration of miconazole, polymyxin B and prednisolone (Surolan; Janssen-Cilag).

The crusts were boiled up in 10 per cent potassium hydroxide and the sediment was examined after 30 minutes. All stages of *Notoedres* species mites could be detected, from ovum to adult. Two adult, gravid females measured 238·4 µm in length (from the tip of the gnathosoma to the end of the idiosoma) x 201·6 µm in width, and 249·6 µm x 217·6 µm, respectively; one adult male measured 150·4 µm x 115·2 µm. Two larvae measured 110·4 µm x 84·8 µm and 113·6 µm x 88 µm, respectively. The mites were identified as *N cati* on the basis of morphological features (Figs 2, 3). The dorsal scales present in *N cati* are absent in *N muris* or *Notoedres centrifera (douglasi)*, which have dorsal striations (Lavoipierre 1964). *N oudemansi* may also have dorsal scale-like formations, but these mites are larger (adult females are approximately 362 µm x 342 µm), the dorsal setae do not exceed 11 µm (Fig 2), and they possess an additional pair of ventral setae (*g p*) between the fourth coxae, which could not be detected in the present case (Fig 3) (Fain 1965). We identified only the ventral pair of setae (cx III) between the third coxae (Fig 3). Another notoedric mite, observed in mice, which has dorsal scale-like formation, is *Notoedres musculi*, but this mite is much larger (adult females approximately 400 µm x 375 µm), the anus is, compared with *N cati*, near the body margin, and the dorsal setae are weakly developed (Fain 1965). To the authors' knowledge, this is the first description of patent *N cati* infection in an insectivore.

The clinical signs in the animal had improved significantly 10 days after the initial treatment. The crusts had almost completely resolved, with only small crusts remaining on the hedgehog's paws and ears. Native preparation of the crusts and examination for dermatophytes under a light ophthalmic microscope was negative. However, there was a growth of suspicious colonies on Dermasel selective agar (Oxoid) after seven days' incubation at room temperature. The colonies were identified morphologically as the dermatophyte *Trichophyton mentagrophytes* var *erinacei* (Smith and Marples 1963). The diagnosis was confirmed using lactophenol blue staining. Numerous thin and elongated microconidia (4·6 µm x 1·3 µm wide), mainly occurring along the sides of the mycelium, could be identified. Takahashi and others (2003) reported infection with this dermatophyte in seven (39 per cent) of 18 pet African pygmy hedgehogs in Japan. A mixed infection of *T mentagrophytes* var *erinacei* and *Caparinia tripilis* mites has also been described in pet African pygmy hedgehogs (Takahashi and others 2002). There was rapid improvement after initial treatment against ectoparasites in the present case, so the fungal infection was thought to have been an opportunistic infection. However, due to the zoonotic potential of *T mentagrophytes* var *erinacei* (Gregory and English 1975), treatment with 25 to 50 mg griseofulvin (Likuden; Intervet), administered orally daily for four weeks, and 100 mg/ml water enilconazole washes (Imaverol; Janssen-Cilag), on four occasions, four days apart, was initiated (Beck sold.

There are published reports of possible *N cati* transmission from infected domestic cats to human beings worldwide (for example, Chakrabarti 1986); therefore, caution is advised when handling infected hedgehogs.

FIG 1: African pygmy hedgehog (*Atelerix albiventris*) with thick, hard, white and yellow crusts covering the head area (arrows) and ears (arrowhead)

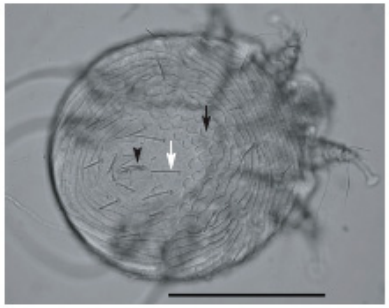

FIG 2: Dorsal idiosoma of an adult, gravid female *Notoedres cati* from an African pygmy hedgehog. The anus on the dorsal surface (arrowhead) characterising the genus, scalloped scales (black arrow) and dorsal setae measuring more than 20 µm in length (white arrow) can be seen. Bar=125 µm

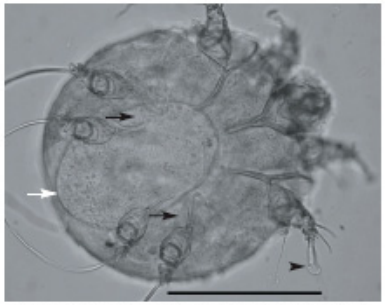

FIG 3: Ventral view of the gravid female *Notoedres cati* mite shown in Fig 2, showing the ventral setae cx III (black arrows), an ovum (white arrow) and the typical sarcoptiform pretarsus with a long, unbranched pedicle with a sucker on the second leg (arrowhead). Bar=125 µm

ACKNOWLEDGEMENTS

The authors thank Cornelia Siebertz (VetMedLabor Ludwigsburg) for culturing and identifying *T mentagrophytes* var *erinacei*, and Dr Carlos Hermosilla, Institute of Parasitology, University of Giessen, for his helpful comments.

References

BECK, W. (2003) Praxisrelevante Ektoparasitosen und Dermatophytosen bei kleinen Heimsäugern, Vögeln und Reptilien. *Praktischer Tierarzt* 84, 752-762
BOWMAN, D. D., HENDRIX, C. M., LINDSAY, D.S. & BARR, S. C. (2001) The arthropods. In Feline Clinical Parasitology. Ames, Iowa State University Press. pp 355-447
CHAKRABARTI, A. (1986) Human notoedric scabies from contact with cats infested with *Notoedres cati*. *International Journal of Dermatology* 25, 646-648
FAIN, A. (1965) Notes sur le genre *Notoedres* Railliet, 1895 (Sacroptidae: Sarcoptiformes). *Acarologia* 7, 321-342
GREGORY, M. W. (1981) Mites of the hedgehog *Erinaceus albiventris* Wagner in Kenya: observations on the prevalence and pathogenicity of *Notoedres oudemansi* Fain, *Caparinia erinacei* Fain and *Rodentopus sciuri* Fain. *Parasitology* 82, 149-157
GREGORY, M. W. & ENGLISH, M. P. (1975) *Arthroderma benhamiae* infection in the central African hedgehog, *Erinaceus albiventris*, and a report of a human case. *Mycopathologia* 55, 143-147
HEATH, A. C. G., BUSH-MUNRO, R. M. & RUTHERFORD, D. M. (1971) The hedgehog – a new host record for *Notoedres muris* (Acari: Sarcoptidae). *New Zealand Entomologist* 5, 100-103
KLOMPEN, H. (1992) Phylogenetic relationships in the mite family Sarcoptidae (Acari: Astigmata). *Miscellaneous Publications of the Museum of Zoology, University of Michigan* 180, 1-159
LAVOIPIERRE, M. M. (1964) Mange mites of the genus *Notoedres* (Acari: Sarcoptidae) with description of two new species and remarks on notoedric mange in the squirrel and the vole. *Journal of Medical Entomology* 1, 5-17
NINOMIYA, H. & OGATA, M. (2002) Notoedric mange in two free-ranging North American racoons (*Procyon lotor*) in Japan. *Veterinary Dermatology* 13, 119-121
NINOMIYA, H., OGATA, M. & MAKINO, T. (2003) Notoedric mange in free-ranging masked palm civets (*Paguma larvata*) in Japan. *Veterinary Dermatology* 14, 339-344
ROSEN, T. (2000) Hazardous hedgehogs. *Southern Medical Journal* 93, 936-938
SMITH, J. M. B. & MARPLES, M. J. (1963) *Trichophyton mentagrophytes* var *erinacei*. *Sabouraudia* 3, 1-10
TAKAHASHI, T., HARITANI, K., SANO, A., TAKIZAWA, K., FUKUSHIMA,

Aus dem Institut für Vergleichende Tropenmedizin und Parasitologie (Vorstand: Prof. Dr. K. Pfister) der Tierärztlichen Fakultät der LMU München[1] und der Novartis Tiergesundheit GmbH in Eschborn[2]

Flohbekämpfung bei wildlebenden und in menschlicher Obhut gepflegten Igeln – Ein Therapieansatz mit Nitenpyram (Capstar®)

W. BECK[1], MAREIKE SAUNDERS[2], BETTINA SCHUNACK[2] UND K. PFISTER[1]

Vielen Dank für die Aufmerksamkeit !
Fragen ?